Review Article

Subglottic tracheal stenosis

Antonio D'Andrilli[1], Federico Venuta[2,3], Erino Angelo Rendina[1,3]

[1]Department of Thoracic Surgery, Sant'Andrea Hospital, Sapienza University, Rome, Italy; [2]Department of Thoracic Surgery, Policlinico Umberto I, Sapienza University, Rome, Italy; [3]Lorillard Spencer Cenci Foundation, Rome, Italy

Contributions: (I) Conception and design: A D'Andrilli; (II) Administrative support: None; (III) Provision of study materials or patients: All authors; (IV) Collection and assembly of data: All authors; (V) Data analysis and interpretation: All authors; (VI) Manuscript writing: A D'Andrilli; (VII) Final approval of manuscript: All authors.

Correspondence to: Dr. Antonio D'Andrilli. Department of Thoracic Surgery, Sant'Andrea Hospital, Sapienza University, Via di Grottarossa 1035, 00189 Rome, Italy. Email: adandrilli@hotmail.com.

Abstract: Benign subglottic stenosis represents a major therapeutic challenge. Interventional bronchoscopic treatment has a limited role in this setting due to anatomical and technical reasons. The benefit with these techniques is generally temporary, due to frequent recurrences, need for repeated procedures and risk of extending the area of damage. Laryngotracheal resection is at present the curative treatment of choice. Literature data show that surgical treatment may allow very high success rates at long term with low perioperative morbidity and mortality. Technical aspects and results are reported and discussed.

Keywords: Subglottic stenosis; laryngotracheal resection

Submitted Nov 01, 2015. Accepted for publication Dec 18, 2015.
doi: 10.3978/j.issn.2072-1439.2016.02.03
View this article at: http://dx.doi.org/10.3978/j.issn.2072-1439.2016.02.03

The subglottic space at the cricoid level is the narrowest part of the airway. It extends from the inferior margin of the vocal cords to the lower border of the cricoid cartilage. Subglottic stenosis is generally benign and may be due to a variety of diseases, but post intubation (PI) injury is definitely the most frequent cause. Such injury may be produced by either translaryngeal intubation or tracheostomy (1-5). Translaryngeal intubation may result in damage involving both the glottis and the subglottis. This usually follows periods of prolonged intubation in intensive care units due to the need for mechanical ventilatory support (1-3). At subglottic level, following mucosal ischemia and ulceration produced by the rigid wall of the endotracheal tube, healing occurs with the formation of a firm fibrous scar resulting in varying degree of stenosis. Concentric stenosis is the most frequent finding. However, damage at the glottis and vocal cords most commonly involves the posterior structures with ulceration of the interarytenoid mucosa. This could be responsible for subsequent fibrous stricture in this site with possible extension to the cricoarytenoid joints and limitation of the vocal cords function. Isolated stenosis of the anterior commissure is more rare (3).

Other known causes of subglottic stenosis include airway trauma, inhalation burns and irradiation. A peculiar group of patients with subglottic stenosis is represented by those with idiopathic (ID) stenosis. This disease is characterized by an inflammatory cicatricial stenosis that occurs almost exclusively in women between the third and the fifth decade without other identifiable causes of airway stenosis (6). More rare causes are tracheal infections including bacterial tracheitis, tuberculosis, histoplasmosis and diphtheria, and collagen vascular diseases including Wegner's granulomatosis, relapsing polycondritis, polyarteritis and scleroderma (6).

Treatment of stenosis located in the subglottic region is a major therapeutic challenge. This poses increased technical problems with respect to treatment of lower tracheal stenosis, due to the need for approaching a disease involving the larynx near the vocal cords.

Surgical resections are the first line curative treatment although a number of less invasive alternative therapeutic options are available. Technical aspects and results are here reported and discussed.

© Journal of Thoracic Disease. All rights reserved.

Alternative treatments

Interventional bronchoscopic treatments including laser, mechanical dilation and stenting, whose application in tracheal surgery has greatly increased in recent years, have a limited role in subglottic stenosis due to anatomic and technical reasons (7). Literature data show that only simple stenosis including cases of thin web-like stricture or granuloma can be removed definitively by dilation, laser treatment or laser-assisted mechanical dilation. However, the benefit in more complex lesions is generally temporary, with frequent recurrences, consequent need for repeated procedures and risk of extending the diseased segment (7-9). Especially when a stent is placed, this can enlarge the area of airway injury and be responsible for further complications such as granuloma formation or prosthesis migration (7-8). Moreover, there is general agreement that the use of laser resection for subglottic stenosis should be limited as much as possible because of the risk for damaging the underlying cricoid cartilage (9).

In Brichet's experience, complex stenosis treated with laser and stenting as first approach obtained only a 17.6% success rate (10). The authors concluded that surgery is mandatory for such complex lesions and that interventional bronchoscopic procedure must be considered only in case of emergency to resolve acute respiratory failure due to critical stenosis or for temporary management while evaluating timing to surgery.

Similarly, Galluccio *et al.* (11) analyze results of their large series including 21 cases of subglottic stenosis and conclude that the endoscopic treatment of complex subglottic stenosis is generally contraindicated.

Looking at literature data, there is general convincement that good functional outcome can be obtained with bronchoscopic treatment of benign stenosis if the indication is restricted to tracheal disease excluding subglottic location (12).

Therefore, at present these techniques are mainly employed to stabilize the stenosis before surgery or to achieve an acceptable palliation in patients who are not suitable for surgery.

Temporary Montgomery T-tube and tracheostomy have been considered the only possible alternatives to surgery for a long time. However, these options have the disadvantage of potentially increasing the extent of the tracheal stricture and of favoring bacterial colonization (7). These two problems may be particularly detrimental for patients who are likely to be reconsidered for surgery thanks to improved general and/or local conditions.

Surgery

Historical notes and technical aspects

A stenotic disease involving the subglottic region presents increased technical problems when performing surgical treatment, principally due to the need to extend the resection to the cricoid cartilage, next to the vocal cords (*Figure 1*). Particular care must be taken when considering resection of the cricoid cartilage since the laryngeal nerves have access into the airway wall at the level of its posterior plate, whose upper border supports the arytenoid cartilages which play a major role in vocal cord function.

The initial experience of segmental resections of the cricoid cartilage was reported by Ogura and Powers in 1964 (13) and included a series of seven patients undergoing primary thyro-tracheal anastomosis. However, no attempt to preserve the laryngeal nerves was required since they were irreversibly damaged on both sides as a result of the trauma. In 1974 Gerwat and Bryce (14) described for the first time an original technique to preserve the posterior cricoid plate and the recurrent nerves above the level of the crico-thyroid joints by using an oblique line of resection in order to remove only the anterior cricoid arch. The upper transection line begins at the inferior border of the thyroid cartilage anteriorly and passes below the crico-thyroid joints posteriorly. However, this technique allowed a limited extent of resection of the posterior subglottic structures. Pearson *et al.* in 1975 (15) proposed a modification of this technique which allowed transverse resection of the subglottic airway at any level below the vocal cords, with preservation of a posterior shell of the cricoid cartilage sparing the laryngeal nerves. With this technique the line of division passes few millimeters below the vocal cords. Thus, primary thyro-tracheal anastomosis can be performed at less than 1 cm from the vocal cords. This is still the most frequently used technique to date. Before resecting the anterior portion of the cricoid arch, the trachea is sectioned below the stenotic segment, and the distal airway is intubated through the operative field by an armored endotracheal tube (*Figure 1*). When isolating circumferentially the diseased segment of the upper trachea there is generally no need to identify the laryngeal nerves (which are frequently involved in the surrounding scar tissue), since maintaining dissection close to the surface of the trachea can be sufficient to avoid injuries to these structures. The antero-lateral aspect of the cricoid cartilage is then freed completely from their perichondrial cover and resected (*Figure 1A*). A discrepancy in diameter between

© Journal of Thoracic Disease. All rights reserved.

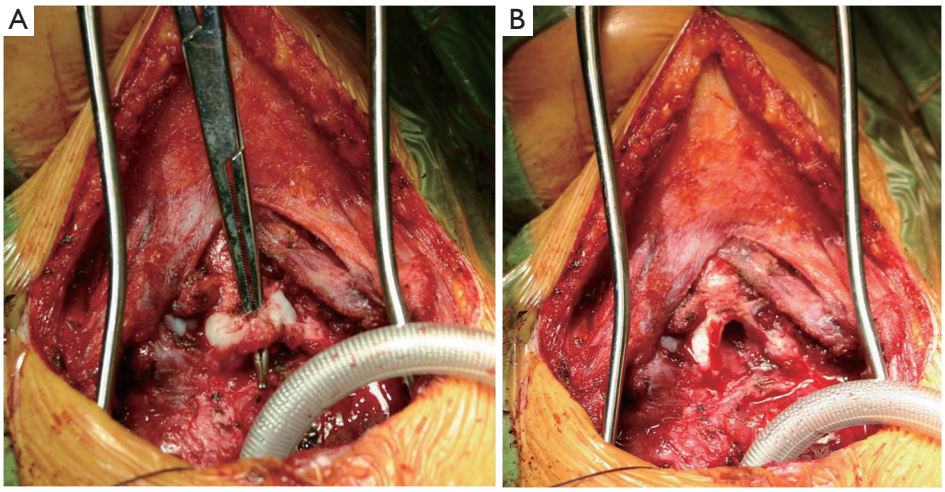

Figure 1 Intraoperative pictures of laryngotracheal resection for subglottic stenosis. (A) The anterior cricoid ring has been prepared for resection. The distal tracheal stump has been intubated through the operative field; (B) laryngotracheal resection including the anterior cricoid ring has been completed.

the lumen of the subglottic airway and the distal trachea at the time of reconstruction is unavoidable (*Figure 1B*). The end-to-end primary thyro-tracheal anastomosis is usually performed using interrupted sutures of 3–0 or 4–0 absorbable material [usually polydioxanone (PDS)]. Technical variation may include a running suture for the posterior membranous wall of the anastomosis.

Although Pearson and colleagues (15) suggested plicating the pars membranacea of the distal trachea to reduce this difference in terms of diameter, this procedure may be not necessary in many cases, since the elasticity of the distal trachea allows adequate compensation. In some patients the post-intubation subglottic stenosis may be complicated by glottic injury at the level of the posterior interarytenoid space. In such cases, when the interarytenoid scar is excised, a posterior mucosal defect is created. This defect can be covered by a pedicled flap of pars membranacea fashioned from the distal trachea and created by resecting one or two cartilaginous rings on the anterior aspect as described by Grillo (16).

Some other reconstruction techniques have been proposed in more recent years to manage laryngotracheal stenosis, especially when also the glottis is involved, with the aim of obtaining a permanent enlargement of the subglottic airway. These procedures, principally popularized by otorinolaryngologists, include the vertical division of the anterior wall of the thyroid cartilage and the posterior cricoid plate after resection of the anterior cricoid arch with the possible insertion of an autologous tissue graft between the divided cartilaginous portions. Free pieces of bone or cartilage have been used as grafts.

Maddaus *et al.* (17) described a technique of laryngotracheal reconstruction indicated for stenosis close to the vocal cords (less than 5 mm) when their function is not compromised. Once the anterior cricoid arch is removed, the thyroid cartilage must be incised vertically in the midline to protect the vocal cords. Afterward, the affected mucosa is removed by incising the upper limit of the stenosis with the scalpel. The posterior cricoid plate can be then resurfaced by a membranous flap tailored from the distal tracheal stump.

A different technique has been described by Couraud (18-20). This is generally indicated for stenosis with current involvement of the glottis and compromised vocal cords function or in case of larynx cartilages damage by previous procedures (laser, tracheostomy, Montgomery T tube, surgery). In this operation after laryngofissure, the cricoid plate is incised and divided at the midline. Free cartilagine or bone graft can be interposed to enlarge the larynx lumen. The use of these techniques is more frequent in the pediatric population (21).

In the current authors' experience a variation of the standard Pearson technique with associated laryngoplasty was employed in some patients showing actual involvement of the vocal cords; after resection of the cricoid ring and crico-thyroid membrane, the thyroid cartilage was incised longitudinally on the midline for an extent of 1–1.5 cm (partial laryngofissure). The margins were then retracted

© Journal of Thoracic Disease. All rights reserved.

laterally to increase the airway space and the lower trachea was directly anastomosed to the retracted ends of the incised thyroid cartilage.

Perioperative management

Preoperative assessment is principally based on laryngotracheal endoscopic examination with the aim to evaluate mobility and trophicity of the vocal cords, severity and extent of the stricture, grade of inflammation and presence of edema or malacia. Laryngotracheal resection is generally performed after having assessed the stenosis stabilization endoscopically.

Completion of preoperative study with neck and chest computed tomography (CT) scan (spiral technique) is usually recommended to allow a more precise evaluation of the tracheal wall status (calcification, malacia) and of the extraluminal structures and tissue.

In patients with evidence of infection at the tracheostomy site, the present authors recommend systemic and local antibiotic treatment until sterilization proved by microbiology is achieved (7).

In cases of tight stenosis, some problems may arise at the time of intubation, before the resection; the stenosis can be dilated by a gum-tipped bougie or by a rigid bronchoscope. According to our experience (22), a small calibre (4–4.5) endotracheal tube can be passed through the stenosis in many cases of severe stricture, and this is usually sufficient for adequate ventilation until the trachea is exposed and incised allowing cross-field intubation. Occasionally the tube can be placed immediately above the stenosis.

Two strong chin-chest sutures are generally placed at the end of operation to maintain patient cervical flexion and are usually removed after 4–8 days depending on the length of the resected segment and on the anastomosis tension degree (22).

There is no general agreement among surgeons regarding the airway management at the end of the operation. Some authors (23,24) advocate immediate extubation in the operative room. According to this approach, if the patient is not able to breathe spontaneously or presents glottis edema, a small uncuffed endotracheal tube is left in site and removed after 48 to 72 hours. If the anastomosis is still a concern a small tracheostomy is placed two rings below the anastomosis.

Some other surgeons, including the current authors (18,22,25), use to leave a nasotracheal tube in place uncuffed in the awakened patient for 24 hours and then to remove it after bronchoscopic check of the anastomosis and vocal cords. The tube is kept with the tip distal to the anastomosis to protect it and to allow safe tracheobronchial toilette. In patients with postoperative glottis edema the tube can be left for a longer time while administering steroids.

When the thyro-tracheal anastomosis is performed very close to the vocal cords there is an unpredictable risk of post-operative glottic edema. This complication can be managed in different ways according to the surgeon's preference. Some authors recommend to place, at the end of operation, a small tracheostomy or a silicone Montgomery T-tube distal to the anastomosis (26). These can be left in place for a variable period of time: weeks or even months, depending on the status of the glottis and of the anastomosis. The present authors prefer to leave the naso-tracheal tube in place for a longer time (48–72 hours) after surgery while administering steroid therapy, since they have proved that with this strategy definitive extubation within few days can be obtained in almost all patients without sequelae (22).

Similarly, there is no consensus regarding the use of steroids after resection. In the present authors' practice the use of low-dose steroids is routinely considered during the postoperative course with the aim of reducing glottis and anastomosis edema. Over their long term experience no related impairment of the anastomosis healing has been observed (7,22,27).

According to the Massachussetts General Hospital group the use of steroids after laryngotracheal reconstruction should be avoided and limited only to cases of severe glottis edema with administration of short course high-dose therapy (24).

Patients' follow-up is principally based on clinical evaluation and tracheo-bronchoscopic controls (*Figure 2*). CT scan can be considered in selected cases when doubts on the tracheal wall status exist.

Results of surgery

Pearson and colleagues (15,17) reported the results of a series including 38 patients treated using their technique of partial cricoid resection and primary thyro-tracheal anastomosis. Recurrence of stenosis occurred in two patients and was successfully managed by re-resection in one case and by dilation and laser ablation in the other. There was no mortality. Ultimately, therefore, good results were achieved in all patients.

Grillo and coworkers (28,29) reported the outcome of 80 patients undergoing subglottic resection and

© Journal of Thoracic Disease. All rights reserved.

reconstruction with the use of their modified technique. Fifty of these patients had a PI injury. There was one operative death. All 49 survivors of this group presented satisfactory to excellent results.

One of the largest published experiences of laryngotracheal resection has been reported by Couraud and colleagues (30), which included 57 patients with post-intubation stenosis involving the subglottic region alone or in combination with the larynx out of a total of 217 patients with benign tracheal stenosis. Results were excellent or good in 98% of the cases. There was one perioperative death (1.8% overall mortality).

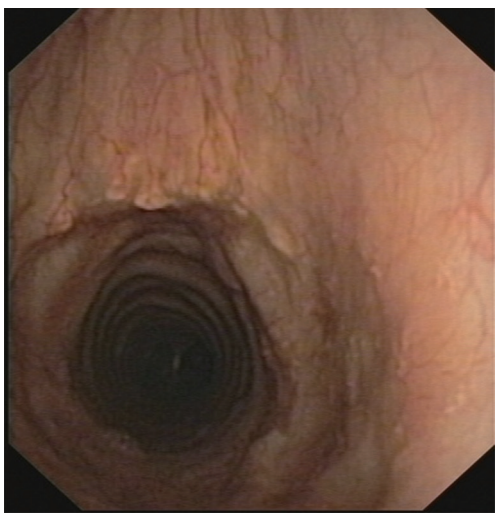

Figure 2 Broncoscopic check of the anastomosis 3 months after laryngotracheal resection.

To date single-staged laryngotracheal resection with primary end-to-end anastomosis has proved to offer the best option of cure for benign subglottic stenosis allowing definitive and stable high success rate. Major published series in this setting report good to excellent outcome in more than 90% of patients at long term with perioperative mortality under 1–2% (23,25,26,29-32). Major surgical morbidity is generally limited, with restenosis rates ranging between 0% and 11% (23,25,26,29-32), anastomotic dehiscence rates of 0–5% (9-16) and reoperation rate of 0–6% (13,25,26,29-32) (*Table 1*).

We have recently reported our experience of laryngotracheal resection for benign stenosis with the Pearson technique over a 25-year period reporting long-term results (mean follow-up 52 months) from a series of 109 consecutive patients (32). Resection of a tracheal segment longer than 4.5 cm was performed in 14 patients. Definitive extubation was possible in the first postoperative day in 98 patients. Four patients, after extubation at 24 hours, had to be reintubated within a few hours because of glottic edema. Definitive reextubation was possible, after steroid therapy, 2 days later in one patient and 3 days later in other two patients. One patient could not be re-extubated because of persistent glottis edema and received permanent tracheostomy. In six patients the nasotracheal tube was left in site for a longer time (2 days in four patients, 3 days in two patients) because of severe glottis edema visible at operation without need for further reintubation.

Immediate excellent or good anatomic and functional results were observed in 90.8% of the cases. Eight patients (7.4%) presented with recurrence of stenosis that was

Table 1 Main published series of patients undergoing laryngotracheal resection for benign stenosis in the last two decades

Authors [year]	Pts (n)	Diagnosis	Results		Restenosis	Dehiscence	Reoperation	Mortality
			Success (%)	Failure (%)	(%)	(%)	(%)	(%)
Grillo *et al.* [1995] (29)	62	PI	92.0	8.0	8.1*	8.1*	0.0	2.4
Couraud *et al.* [1995] (30)	57	PI, PT, ID	98.2	1.8	0.0	1.8	0.0	1.8
Macchiarini *et al.* [2001] (31)	45	PI	96.0	4.0	4.4	0.0	2.2	2.0
Ashiku *et al.* [2004] (23)	73	ID	91.0	9.0	9.5	0.0	0.0	0.0
Marulli *et al.* [2008] (25)	37	PI, PT, ID	Early 89.0; definitive 97.0	Early 11.0; definitive 3.0	5.5	5.5	5.4	0.0
Morcillo *et al.* [2013] (26)	60	ID	Early 91.7; definitive 98.0	Early 8.3; definitive 2.0	3.3	3.3	6.7	0.0
D'Andrilli *et al.* [2015] (32)	108	PI, ID	Early 91.0; definitive 99.1	Early 9.0; definitive 0.9	7.4	0.9	0.0	0.0

*, restenosis + dehiscence. PI, post intubation; PT, post-traumatic; ID, idiopathic.

© Journal of Thoracic Disease. All rights reserved.

successfully treated by endoscopic procedures in all cases. This proves that even in patients experiencing early failure of the surgical procedure, final and durable success can be still obtained without reoperation. One patient (0.9%) presented with anastomotic dehiscence that required a temporary tracheostomy closed after one year with no sequelae. One patient (0.9%) with persistent glottis edema received permanent tracheostomy.

Definitive results at long-term were good or excellent in 94.5% and satisfactory in 4.6% of the patients. This series included 28 post-coma patients with neurological or psychiatric disorders that severely limited their cooperation in the postoperative period. Good to excellent outcome rates in this group were similar to those observed in the remaining population, suggesting that such condition should not be considered as absolute contraindication for surgery any more.

Published results of laryngotracheal resection associated laryngoplasty (Maddaus-type or Couraud-type techniques) for stenosis close to or involving the vocal cords are very limited and show wide variability among different studies. Systematic need for prolonged stenting after the operation is described with these techniques.

Maddaus *et al.* reported a series of 53 circumferential subglottic resections that included also 15 patients presenting with combined laryngeal and subglottic lesions (17). These complex stenoses were managed by synchronous subglottic resection and concomitant laryngofissure for laryngeal reconstruction according to the previously described technique. Decannulation and subsequent stable satisfactory results were achieved in all the patients of this subgroup but two. However, the need for temporary laryngotracheal stent (usually Montgomery T-tube) after laryngeal reconstruction was the rule with a duration ranging between 3 and 42 months.

McCaffrey (33) has reported a series of 21 patients with subglottic stenosis treated with the interposition of a costal cartilage graft in the anterior vertical incision of the cricoid and the thyroid cartilage. Although the incidence of satisfactory results was high (76%), there was a 24% rate of patients that could not be extubated. Terra (34) has published his experience of laryngotracheal reconstruction for glottic/subglottic stenosis using a laryngeal split with anterior and posterior interposition of a rib cartilage graft. Eighty percent of patients were completely decannulated after a mean of 23.4 months. A 20% tracheocutaneous fistula rate was reported in this series.

Particular interest has been reported in the literature when considering results of laryngotracheal resection for ID subglottic stenosis. This rare disease with unknown cause has been described by some authors (35) as potentially progressive, generally associated with severe inflammation which often involves the vocal cords or the space just below. Due to such characteristics, controversies still exist concerning the optimal management strategy and the appropriateness of surgical resection. Because of the high risk of leaving partially involved tissue with possible consequences for future recurrence, some authors believe that crycotracheal resection should not be indicated (35).

Dedo and Catten (35) after having analysed a series of 52 patients with ID stenosis concluded that this is a progressive disease that cannot be cured and hence advocated repeated palliative procedures indefinitely. In this experience all seven patients treated with resection had restenosis. The 43 patients undergoing only endoscopic treatments received an average of 8 procedures each, but 17 patients required permanent tracheostomy and only 21 patients appeared disease-free over the long term.

However, Grillo *et al.* in 1993 (6) reported a 91% rate of good to excellent outcome over a series of 35 single-staged laryngotracheal resections for ID stenosis. Similarly, Ashiku *et al.* (23) observed the same rate (91%) of patients with good to excellent long term results without need for further intervention. More recently, Morcillo *et al.* (26) in a Spanish multi-institutional study which included 60 patients receiving resection using different techniques (with or without postoperative temporary stenting) reported a 97% final success rate with no mortality.

In our series all 16 patients with ID stenosis undergoing laryngotracheal resection showed satisfactory to excellent long term results with no recurrence (32). Most of them presented with upper limit of stenosis and inflammation close to the glottis. Demanding excision of extra-mucosal scar tissue at the level of the cricoid cartilage was required in most cases, especially on the posterior plane with thyro-tracheal anastomosis performed close to the vocal cords. Based on evidences coming from our experience and other large series in the literature, we and other authors believe that single-staged laryngotracheal resection and reconstruction can be considered an effective definitive cure for such patients allowing stable long term results if the operation is perfomed with correct timing and adequate technical experience (23,26,32).

In conclusion results from the literature and from the present authors' experience confirm that laryngotracheal resection represents the curative treatment of choice for

© Journal of Thoracic Disease. All rights reserved.

benign subglottic stenosis allowing high success rates at long term. Most patients experiencing major postoperative complications can be successfully treated by non operative (generally endoscopic) procedures achieving stable results over time. Low compliance patients with neurologic and/or psychiatric disorders, and patients with ID stenosis show no increased failure and complication rates after surgical resection.

Acknowledgements

We wish to thank Dr. Marta Silvi for data management and editorial work.

Footnote

Conflicts of Interest: The authors have no conflicts of interest to declare.

References

1. Colice GL, Stukel TA, Dain B. Laryngeal complications of prolonged intubation. Chest 1989;96:877-84.
2. Pearson FG, Goldberg M, da Silva AJ. A prospective study of tracheal injury complicating tracheostomy with a cuffed tube. Ann Otol Rhinol Laryngol 1968;77:867-82.
3. Pearson FG, Andrews MJ. Detection and management of tracheal stenosis following cuffed tube tracheostomy. Ann Thorac Surg 1971;12:359-74.
4. Wood DE. Bronchoscopic preparation for airway resection. Chest Surg Clin N Am 2001;11:735-48.
5. Wain JC. Postintubation tracheal stenosis. Chest Surg Clin N Am 2003;13:231-46.
6. Grillo HC, Mark EJ, Mathisen DJ, et al. Idiopathic laryngotracheal stenosis and its management. Ann Thorac Surg 1993;56:80-7.
7. Ciccone AM, De Giacomo T, Venuta F, et al. Operative and non-operative treatment of benign subglottic laryngotracheal stenosis. Eur J Cardiothorac Surg 2004;26:818-22.
8. D'Andrilli A, Rendina EA, Venuta F. Tracheal surgery. Monaldi Arch Chest Dis 2010;73:105-15.
9. Maddaus MA, Pearson FG. Postintubation injury. In: Patterson GA, Pearson FG, Cooper JD, et al., editors. Pearson's Thoracic and Esophageal Surgery, 3rd Edition. Philadelphia: Churchill Livingstone, 2008:256.
10. Brichet A, Verkindre C, Dupont J, et al. Multidisciplinary approach to management of postintubation tracheal stenoses. Eur Respir J 1999;13:888-93.
11. Galluccio G, Lucantoni G, Battistoni P, et al. Interventional endoscopy in the management of benign tracheal stenoses: definitive treatment at long-term follow-up. Eur J Cardiothorac Surg 2009;35:429-33; discussion 933-4.
12. Melkane AE, Matar NE, Haddad AC, et al. Management of postintubation tracheal stenosis: appropriate indications make outcome differences. Respiration 2010;79:395-401.
13. Ogura JH, Powers WE. Functional restitution of traumatic stenosis of the larynx and pharynx. Laryngoscope 1964;74:1081-110.
14. Gerwat J, Bryce DP. The management of subglottic laryngeal stenosis by resection and direct anastomosis. Laryngoscope 1974;84:940-57.
15. Pearson FG, Cooper JD, Nelems JM, et al. Primary tracheal anastomosis after resection of the cricoid cartilage with preservation of recurrent laryngeal nerves. J Thorac Cardiovasc Surg 1975;70:806-16.
16. Grillo HC. Primary reconstruction of airway after resection of subglottic laryngeal and upper tracheal stenosis. Ann Thorac Surg 1982;33:3-18.
17. Maddaus MA, Toth JL, Gullane PJ, et al. Subglottic tracheal resection and synchronous laryngeal reconstruction. J Thorac Cardiovasc Surg 1992;104:1443-50.
18. Couraud L, Chevalier P, Bruneteau A, et al. Treatment of tracheal stenosis after tracheotomy. Therapeutic indications, preparation for the intervention. Apropos of 9 resections in 15 cases of acute respiratory insufficiency. Ann Chir Thorac Cardiovasc 1969;8:791-7.
19. Couraud L, Jougon JB, Ballester M. Techniques of management of subglottic stenoses with glottic and supraglottic problems. Chest Surg Clin N Am 1996;6:791-809.
20. Couraud L, Martigne C, Houdelette P, et al. Value of cricoid resection in cricotracheal stenosis following intubation (author's transl). Ann Chir 1979;33:242-6.
21. Jaquet Y, Lang F, Pilloud R, et al. Partial cricotracheal resection for pediatric subglottic stenosis: long-term outcome in 57 patients. J Thorac Cardiovasc Surg 2005;130:726-32.
22. D'Andrilli A, Ciccone AM, Venuta F, et al. Long-term results of laryngotracheal resection for benign stenosis. Eur J Cardiothorac Surg 2008;33:440-3.
23. Ashiku SK, Kuzucu A, Grillo HC, et al. Idiopathic laryngotracheal stenosis: effective definitive treatment with laryngotracheal resection. J Thorac Cardiovasc Surg 2004;127:99-107.
24. Wright CD, Grillo HC, Wain JC, et al. Anastomotic complications after tracheal resection: prognostic factors and

© Journal of Thoracic Disease. All rights reserved.

management. J Thorac Cardiovasc Surg 2004;128:731-9.
25. Marulli G, Rizzardi G, Bortolotti L, et al. Single-staged laryngotracheal resection and reconstruction for benign strictures in adults. Interact Cardiovasc Thorac Surg 2008;7:227-30; discussion 230.
26. Morcillo A, Wins R, Gómez-Caro A, et al. Single-staged laryngotracheal reconstruction for idiopathic tracheal stenosis. Ann Thorac Surg 2013;95:433-9; discussion 439.
27. D'Andrilli A, Venuta F, Maurizi G, et al. Bronchial and arterial sleeve resection after induction therapy for lung cancer. Thorac Surg Clin 2014;24:411-21.
28. Grillo HC, Mathisen DJ, et al. Laryngotracheal resection and reconstruction for subglottic stenosis. Ann Thorac Surg 1992;53:54-63.
29. Grillo HC, Donahue DM, Mathisen DJ, et al. Postintubation tracheal stenosis. Treatment and results. J Thorac Cardiovasc Surg 1995;109:486-92; discussion 492-3.
30. Couraud L, Jougon JB, Velly JF. Surgical treatment of nontumoral stenoses of the upper airway. Ann Thorac Surg 1995;60:250-9; discussion 259-60.
31. Macchiarini P, Verhoye JP, Chapelier A, et al. Partial cricoidectomy with primary thyrotracheal anastomosis for postintubation subglottic stenosis. J Thorac Cardiovasc Surg 2001;121:68-76.
32. D'Andrilli A, Maurizi G, Andreetti C, et al. Long-term results of laryngotracheal resection for benign stenosis from a series of 109 consecutive patients†. Eur J Cardiothorac Surg 2016. [Epub ahead of print].
33. McCaffrey TV. Management of subglottic stenosis in the adult. Ann Otol Rhinol Laryngol 1991;100:90-4.
34. Terra RM, Minamoto H, Carneiro F, et al. Laryngeal split and rib cartilage interpositional grafting: treatment option for glottic/subglottic stenosis in adults. J Thorac Cardiovasc Surg 2009;137:818-23.
35. Dedo HH, Catten MD. Idiopathic progressive subglottic stenosis: findings and treatment in 52 patients. Ann Otol Rhinol Laryngol 2001;110:305-11.

Cite this article as: D'Andrilli A, Venuta F, Rendina EA. Subglottic tracheal stenosis. J Thorac Dis 2016;8(Suppl 2):S140-S147. doi: 10.3978/j.issn.2072-1439.2016.02.03

© Journal of Thoracic Disease. All rights reserved.